



This case report demonstrates the usefulness of PURINA® PRO PLAN® VETERINARY DIETS Feline UR St/Ox Urinary (wet) in the treatment of lower urinary tract disease in the cat.

## A case of cystitis associated with struvite microcalculi

Dr Amélie Nègre

*Clinique Vétérinaire des Remparts,  
Pontoise, France*

### Introduction

Stick was a good-natured domestic cat who was brought in for consultation in the summer with dysuria.

He was a two-year-old castrated male who lived in an apartment and never went outdoors. Although he had no companions he played a lot on his own with his many toys and with his owners. He was a laid-back, very cuddly cat, with owners that fed him on low-end supermarket dry food (private label).

### Clinical examination

This was the first time that Stick had shown urinary symptoms, which the owners had first noticed two days previously. Stick had begun passing small amounts of pink-tinged urine beside his litter box and in the wash basin. He was visiting the litter box more often but was not necessarily soiling it very much. Since the day before, he had been less playful. He was spending a lot of time licking his genitals and was meowing for his owners' attention.

He had no history of other health problems although he had not been vaccinated or wormed.

On clinical examination, his condition was generally good. Stick weighed 4 kg, a normal weight for his size (*photo 1*). Sensitivity was observed on palpation of the bladder, which contained a normal volume of urine.



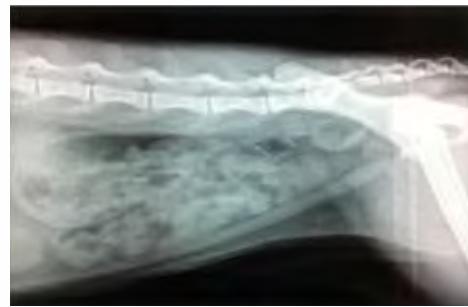
*Photo 1 : Stick at the initial consultation*

### Additional examinations

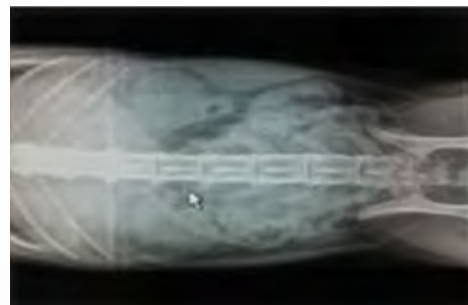The owners understood that their cat had a bladder problem and that further examinations were needed in order to establish an accurate diagnosis and prescribe appropriate treatment.

#### Abdominal radiography

No stones were visible in the urinary tract on abdominal radiography (*photos 2 and 3*).



*Photo 2: lateral view of abdomen*



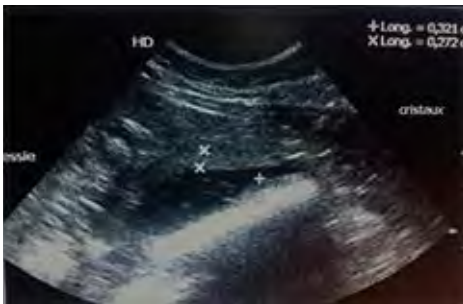*Photo 3: ventro-dorsal view of abdomen*

## Urinary tract ultrasound

Stick was a cooperative cat and allowed himself to be examined in a supine position without restraint.

The bladder wall was thickened (0.32 cm); the thickening was clearly visible in the ventral section (*photo 4*), with the dorsal wall also appearing thickened and hyperechoic. This hyperechoic image was accompanied by a shadow cone partially linked to the presence of the colon.

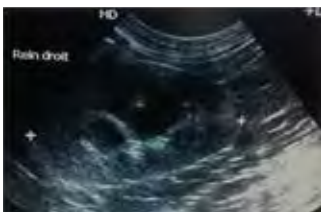The bladder contents were non-uniform: hyperechoic elements in suspension settled gradually on the dorsal wall of the bladder. Images like these are often described as resembling a 'snowstorm' effect. Clearly visible at the caudal pole of the bladder was a mass of deposits 0.27 cm thick, which could be re-suspended when the bladder was mobilised by joggling the ultrasound probe. No individual stones were detected in the bladder.



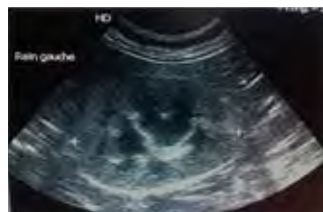
*Photo 4: longitudinal section of the bladder*

The ultrasound appearance of the kidneys was normal (*photos 5 and 6*). No mineral calculi were detected in the kidneys. The ureters were not visible, which is compatible with a normal examination.

The urinary tract ultrasound revealed signs of bladder inflammation and a large quantity of sediment. Cystocentesis was performed to obtain a sample of urine for analysis.



*Photo 5: longitudinal section of the right kidney*

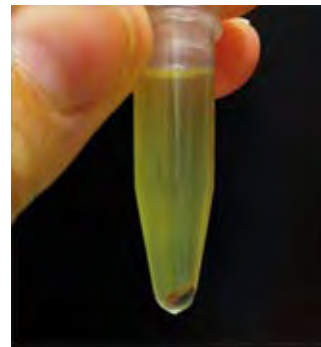

*Photo 6: longitudinal section of the left kidney*

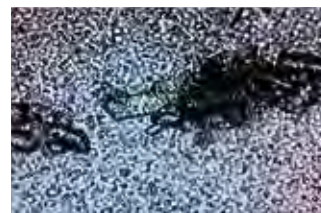## Urinalysis

The urine concentration was normal (specific gravity by refractometry >1.050), which does not tend to point to a urinary tract infection. Nevertheless, a cytobacteriological test was sent to the Vébio laboratory on the same day. The result was negative, ruling out an infectious cause. The urine test strip indicated a pH of 7 and significant haematuria (++++). The latter can be linked to the symptoms of cystitis but may also have been a result of the successive cystocenteses (despite his initial cooperation, Stick became impatient towards the end of the ultrasound procedure and cystocentesis had to be attempted three times in order to obtain sufficient urine for all of the tests).

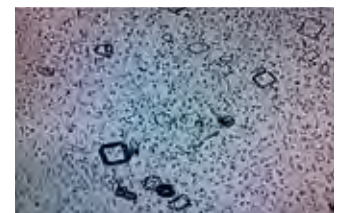After centrifuging the urine, a substantial amount of sediment was observed (*photo 7*). On microscopic examination, it was found to contain large numbers of struvite (magnesium ammonium phosphate) crystals, some of them very large (*photos 8 and 9*), against a background abundant in red blood cells.



*Photo 7: urinary sediment after centrifuging*



*Photo 8: large mass of struvite crystals*



*Photo 9: detail of struvite crystals*

## Blood tests

Biochemistry and haematology results were within normal limits.

## Management and follow-up

### Diagnosis

The clinical and ultrasound signs of lower urinary tract inflammation associated with the presence of large numbers of struvite crystals led to a diagnosis of cystitis associated with struvite microcalculi.

### Treatment

In view of the signs of inflammation and pain observed in Stick (dysuria, stranguria, haematuria, thickening of the bladder wall), medical treatment with an anti-inflammatory (meloxicam) was initiated for five days.

The large numbers of struvite microcalculi visible on ultrasound and under the microscope led to the prescribing of Feline UR Sr/Ox Urinary (wet). The aim was to dissolve the existing bladder microcalculi and to prevent new ones from forming. The wet food was chosen over the dry food in order to increase diuresis and to accelerate evacuation of some of the microcalculi that had accumulated in the bladder. Stick was to eat a tin and a half per day in order to meet his daily energy requirements. He was not to eat anything else, to avoid compromising the effectiveness of treatment pending the check-up in a month's time.

### Follow-up

- Telephone consultation - D0 + 11 days:

The owners were worried. Since the day before, there had been a slight recurrence of the symptoms of dysuria and stranguria. Stick remained fit and healthy; he was eating well and his behaviour was otherwise normal. The owners were advised to resume the anti-inflammatory treatment with meloxicam for another three days. A follow-up bladder ultrasound was suggested but the owners had limited availability and preferred to wait for the check-up in three weeks' time. Stick continued to be fed solely on Feline UR Sr/Ox Urinary (wet).

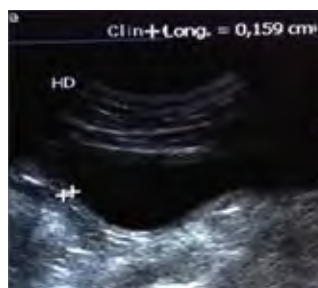- Clinical examination - D0 + 1 month:

Stick's general condition was very good, and he was even more laid-back than at the initial consultation. The owners confirmed that their cat had regained his playful, affectionate behaviour 48 hours after the start of treatment. The disappearance of the urinary symptoms had also been very rapid: Stick had continued to scratch in his litter box for another 2-3 days but without soiling himself. After that, everything had returned to normal until the recurrence on D0 + 10 days, four days after discontinuing the meloxicam. Stick had resumed his frequent trips to the litter box and was meowing on urinating. The resumption of the anti-inflammatory restored normal urination from the day after the telephone consultation.

Stick was happily eating the Feline UR Sr/Ox Urinary (wet). The owners adhered to the prescribed ration and their cat maintained his healthy weight of 4 kg.

- Additional examinations - Follow-up ultrasound

The bladder wall showed no signs of inflammation on ultrasound (*photo 10*). The contents were liquid although a few hyperechoic elements were still visible in suspension during the dynamic examination.



*Photo 10: longitudinal section of the bladder at D0 + 1 month*

- Urinalysis

The urine was still well-concentrated (urine density >1.050). The urine test strip still indicated some presence of blood (+). The pH was stable at 7. Struvite crystals were still visible in the sediment, but in much smaller quantities than on D0.

- Prescription

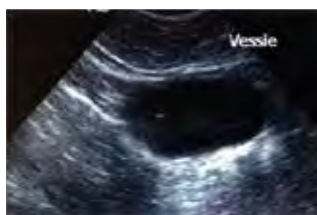
The feeding of Feline UR Sr/Ox Urinary (tinned) was continued until the next check-up.

- Clinical examination - D0 + 2 month:

Stick was fit and healthy; his behaviour was normal and the urinary clinical signs had disappeared.

- Supplementary examinations - Follow-up ultrasound

The ultrasound appearance of the lower urinary tract was normal (*photo 11*).



*Photo 11: longitudinal section of the bladder at D0 + 2 months*

- Urinalysis

The urine was yellow and well-concentrated (density >1.050), and the pH was stable at 7. The sediment showed occasional cells but no crystalluria.

- Blood tests

The biochemistry and haematology results were stable and within normal limits.

 **PURINA**<sup>®</sup>  
**PRO PLAN**<sup>®</sup>  
**VETERINARY**  
**DIETS**

## Discussion and conclusion

For the owners, the undesirable recurrence of symptoms on D0 + 10 days was not serious because the symptoms disappeared again 12 hours after resuming the meloxicam. This clinical recurrence was not surprising given the huge quantity of sediment that had accumulated in the bladder. The owners were satisfied with the effectiveness of the treatment, and had patience because they understood that the diet could not dissolve all of the microcalculi and crystals within ten days. They liked being able to follow their cat's recovery on the ultrasound images.

Stick tolerated Feline UR S<sub>1</sub>/O<sub>x</sub> Urinary (wet) very well and the dietary transition did not cause any digestive problems. The owners had had no worries about Stick's acceptance of the product because he was not a fussy eater. What is more, he enjoyed the change from a dry food to a wet food.

Stick's owners told us that they would recommend this diet to others because they had not believed possible that a diet alone would be sufficient to treat their cat. However, they did mention that the cost of a veterinary diet was an obstacle for them. Switching Stick to the cheaper dry form of Feline UR S<sub>1</sub>/O<sub>x</sub> Urinary was therefore considered in order to prevent a recurrence.

From a veterinary perspective, the product is highly effective: in less than two months, Feline UR S<sub>1</sub>/O<sub>x</sub> Urinary (wet) eliminated the impressive quantity of microcalculi and crystals that had built up in Stick's bladder.

The diet tolerance and palatability were excellent, always an argument in favour of prescribing and repeating the treatment.

I regularly recommend Feline UR S<sub>1</sub>/O<sub>x</sub> Urinary to my professional colleagues because it can be used in cases of both struvite-related and oxalate-related cystitis. The wet form is very useful because it dissolves microcalculi and crystals faster by increasing diuresis, which I considered paramount in this case, given the huge quantity of sediment visible on initial ultrasound.

For some clients, even though they understand the therapeutic benefit of the wet form compared with the dry form, the cost associated with a wet diet remains an obstacle. The vital message that these clients did take away is to stop feeding private label supermarket cat food. To reduce the cost of the diet, in some cases where less sediment is involved, we might suggest mixed feeding of Feline UR S<sub>1</sub>/O<sub>x</sub> Urinary, consisting of 50% wet food and 50% dry food.