



This case report demonstrates the usefulness of PURINA® PRO PLAN® VETERINARY DIETS Feline UR ST/Ox Urinary (canned) in the treatment of lower urinary tract disease in the cat

Treatment of lower urinary tract disease using Feline UR ST/Ox Urinary

Dr. Ducluzaux and Dr. Pereira

CLINIQUE VETERINAIRE,
 53 Route de Romans,
 26120 CHABEUIL, France



Payou is a 1-year-old European neutered male cat, living in a flat with no access to the outside. His diet consists of grocery dry cat food and occasional table scraps. No history of previous disease has been reported. Payou was presented for consultation with dysuria that appeared the day before.

Clinical examination

Payou's general condition was good. His temperature was normal, but he was slightly dehydrated. Abdominal palpation was painful, and a full bladder was identified. The rest of the examination was normal.

Further investigations

Payou was sedated in order to conduct further investigations. Once sedated, urination was easily triggered with pressure thus ruling out urinary obstruction (although some authors consider that cases with clinical signs of lower urinary tract disease and a full bladder involve an obstruction).

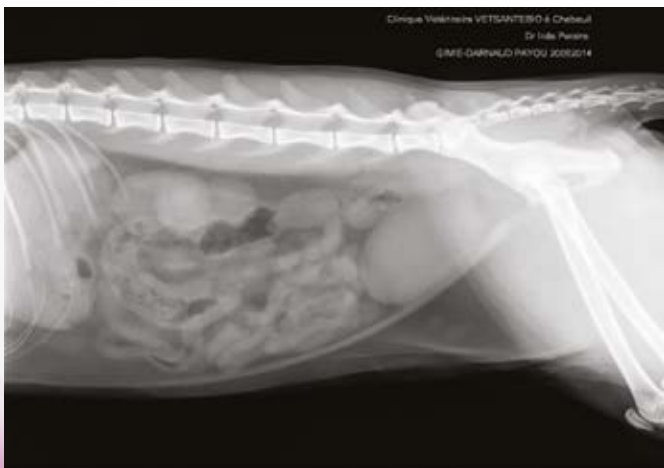


Photo 1 - Payou's abdominal x-ray showing a full bladder and no significant radiopaque elements.

The bladder ultrasound (Photo 2) revealed a full bladder with anechoic content and the presence of intravesical crystals (hyperechoic sediment with a "shadow cone" effect). On the midsagittal section, the crystal layer measured 0.44 x 2.5 cm.

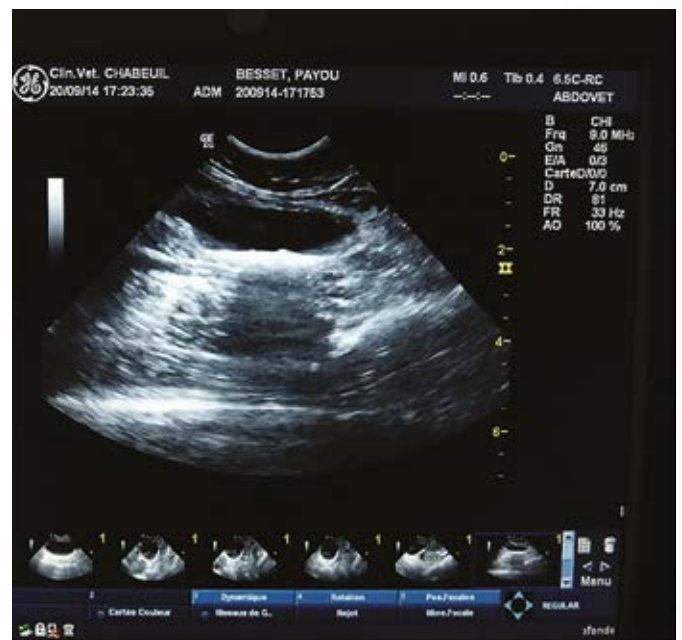

Photo 2 - Payou's ultrasound on Day 0

Urinalysis by cystocentesis was performed at the clinic which revealed a urine specific gravity above 1.050, pH=7 and glycosuria 2+. Examination of the urine sediment revealed numerous magnesium ammonium phosphate crystals (or struvites) as well as red blood cells and leukocytes. The urine culture carried out by an external laboratory was negative.

Complete blood count was normal. Blood biochemistry revealed hyperglycaemia (Glu: 3.5 g/l, normal range: 0.6-1.1). *Diabetes mellitus* was initially suspected given the glycosuria. This was ruled out over the following days because subsequent blood glucose results were within the normal range and glycosuria was no longer observed.

Diagnosis

The presence of urinary struvite crystals suggested a diagnosis of bladder struvite uroliths.

Management and follow-up

To eliminate the maximum number of crystals and rapidly alleviate the pain, the bladder was flushed using a urethral catheter. The catheter was inserted without any difficulty, confirming the absence of obstruction. Lactated Ringer's was infused intravenously for 24 hours to stimulate diuresis. Meloxicam was administered subcutaneously on the first day, and then orally for five days (0.05 mg/kg/day SID) due to its anti-inflammatory and pain relief effects. Prophylactic antibiotics were given because of the risk of iatrogenic infection associated with urethral catheterisation: enrofloxacin (5 mg/kg/day SID). This was selected because of the ease of administration (once daily).

It was decided to switch the cat's food to Feline UR S_T/Ox Urinary (tinned). Other measures such as an improved environment and more water containers were also taken.

At the first check-up one month after starting treatment, Payou was in very good condition and presented no further dysuria episodes. The ultrasound (Photo 3) showed no anomaly and no micro-calculi were observed. Urinalysis revealed a urine pH of 6 and specific gravity of 1.036. There were no crystals in the urinary sediment.

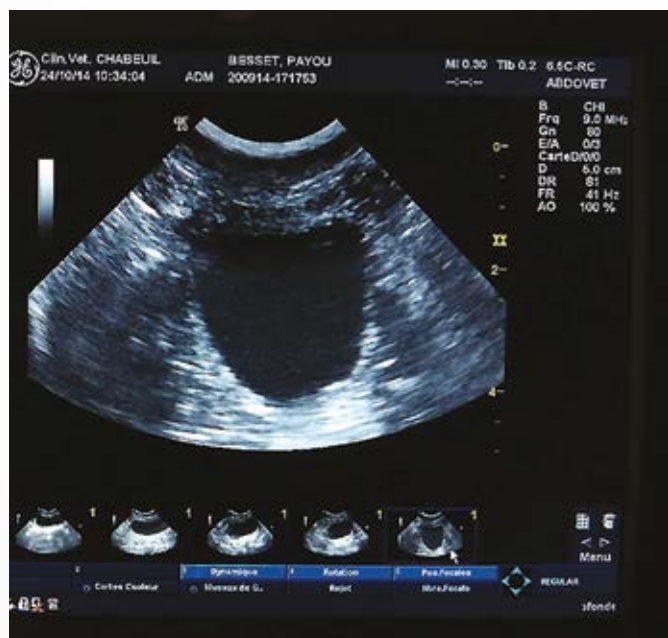

Photo 3 - Payou's bladder ultrasound after one month

The second follow-up visit was two months after starting treatment. Neither the ultrasound nor the urinalysis showed abnormalities. The urinary pH was 5 and specific gravity was 1.050.

Discussion and conclusion

The most common causes of lower urinary tract disease (LUTD) in young cats are urolithiasis and idiopathic cystitis. The micro-calculi can be visualised via ultrasound and, in most cases, crystals can be identified in the urine sediment under a microscope. This case involved MAP (magnesium ammonium phosphate, also known as struvite) crystals, which are the most frequently found, although in recent years the percentage of urolithiasis cases due to calcium oxalate crystals has increased. An alkaline urine and high urine specific gravity favour the appearance of MAP crystals.

Physiological crystalluria and in vitro crystallization must be taken into account when interpreting the clinical significance of MAP crystals in cat urine. In this case, ultrasound evidence of major urinary sediment that was hyperechoic with a "shadow cone" effect, together with the clinical signs, suggested that this crystalluria was pathological.

Struvite calculi and/or micro-calculi can only be dissolved medically by acidifying the urine. We decided to conduct a bladder irrigation in this case with a view to removing most of the micro-calculi. Dissolving the rest of the micro-calculi and preventing recurrence will be achieved via dietary measures, which will help control the pH of the urine (which ideally should be around 6.5) and decrease urine specific gravity. The first goal was achieved; urine pH after 1 and 2 months was 6 and 5, respectively. Regarding urine specific gravity, we believe that the results obtained were not representative. In fact we should point out that the cat was hospitalised the night before the procedure to be sedated the next day. This sharply reduced (or stopped) his fluid intake for 12 hours before the tests and this would therefore have affected the urine concentration. To clarify this point, we would have liked to obtain a urine sample once the cat was at home but the owner was unable to do so.

Overall, Feline UR S_T/Ox Urinary (canned) was well accepted by Payou, and consuming only this was associated with the absence of recurrence of struvite uroliths in this patient. In view of these results, Feline UR S_T/Ox Urinary (canned) seems fully indicated in the case of struvite urolithiasis.