



This case report describes the successful treatment of a case of feline idiopathic cystitis using PURINA® PRO PLAN® VETERINARY DIETS Feline UR St/Ox Urinary (wet and dry formulas) as a dietetic pet food.

## A case of idiopathic cystitis in a 9-year-old neutered male cat

### Dr Christelle Maurey

(Lecturer, Department of Medicine),  
Alfort National School of Veterinary Medicine,  
Maisons-Alfort, France

Horus was a 9-year-old neutered male domestic short haired cat who lived in a flat. Since 2007, Horus had had three episodes of lower urinary tract disease, two of which involved obstruction requiring urethral catheterisation and hospitalisation. The last two episodes occurred within 6 weeks of each other. The latest one occurred a fortnight before the consultation, following the instigation of a fluoxetine-based treatment (RECONCILE™) prescribed after a behavioural consultation to help manage the cat's high levels of anxiety which were manifested by licking at the flanks and abdomen at unusual times and had worsened in recent months. This treatment had since been discontinued.

At the time of the consultation, the animal's diet consisted of Royal Canin URINARY S/O™ (dry formula) *ad libitum*, and Sheba™ and Gourmet Gold™ wet cat food morning and evening.

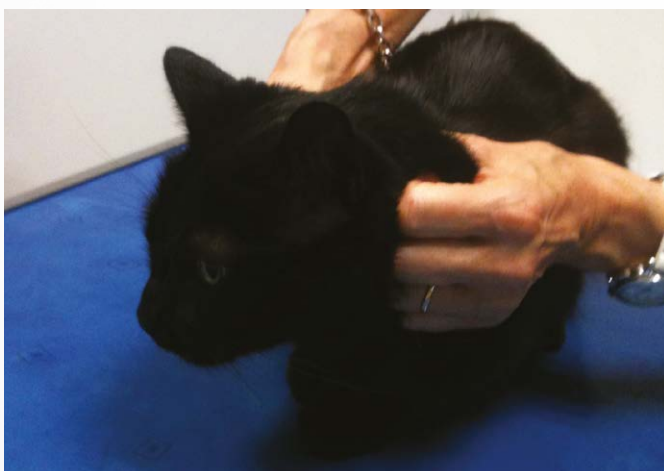

Figure 1: Horus during his initial examination

### Clinical examination

The clinical examination revealed an alert animal in good general condition with a body condition score of 3/5. He weighed 4.4 kg, and his vital signs were normal. Although, he had no bladder symptoms at the time, the owner reported the presence of two recent episodes of inappropriate urination.

The clinical presentation and history thus indicated a 9-year-old neutered male domestic cat in good general condition with recurrent episodes of obstructive or non-obstructive feline lower urinary tract disease.

### Further examinations

The differential diagnoses based on the clinical examination included: idiopathic cystitis, mucus plugs and stones. The anxiety confirmed by the behavioural assessment supported the hypothesis of idiopathic cystitis. A complication of infection or a lower urinary tract tumour could not be ruled out completely but were less likely.

#### a. Blood tests

The laboratory tests revealed no abnormalities.

#### b. Urinalysis

Examination of the urine showed a urinary specific gravity of 1.045 and microscopic haematuria. Examination of the urine sediment revealed some struvite crystals. The urine culture was negative.

#### c. Radiology and ultrasound report

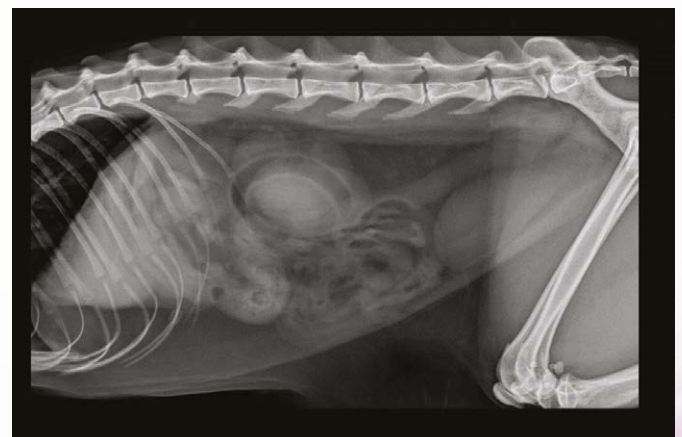
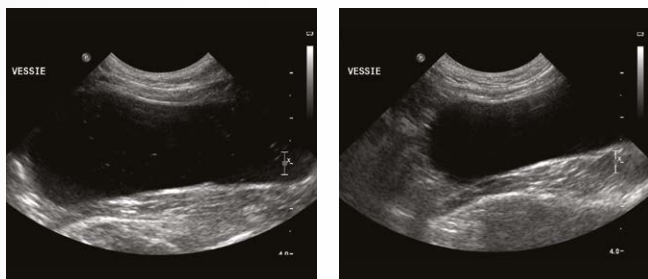


Figure 2: X-ray of Horus, showing no abnormalities

**PURINA**  
**PRO PLAN**  
**VETERINARY**  
**DIETS**

Abdominal radiography revealed no significant abnormalities (see Figure 2). Abdominal ultrasound revealed a moderate quantity of echogenic material in the bladder compatible with cellular debris or crystals (see Figures 3 and 4).



Figures 3 and 4: Ultrasound image of Horus's bladder.

## Diagnosis

In the light of this cat's history of anxiety, his clinical signs and ruling out other differential diagnoses based on laboratory work and imaging, a diagnosis of idiopathic cystitis was made.

## Therapeutic measures and follow-up

Horus was put on a diet of PURINA® PRO PLAN® VETERINARY DIETS Feline UR St/Ox Urinary in wet (one can per day) and dry (ad libitum) form. He accepted the change in diet very well. The follow-up examination conducted 1 month later (Figure 3) showed an animal in good general condition without any urinary problems. The ultrasound examination of the bladder showed the same abnormalities (presence of echogenic material in the bladder).

The examinations performed at 2 and 4 months (Figures 5 and 6 respectively) showed that the cat was still in good general condition, continued to accept the ration very well and had had no recurrences of lower urinary tract disease. The episodes of inappropriate urination had become increasingly rare. The bladder ultrasound performed at 4 months showed the echogenic material inside the bladder had almost disappeared.

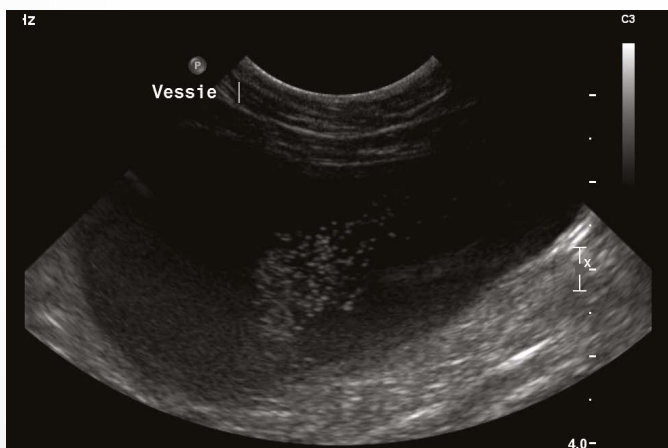


Figure 5: Ultrasound image of Horus at T+2 months

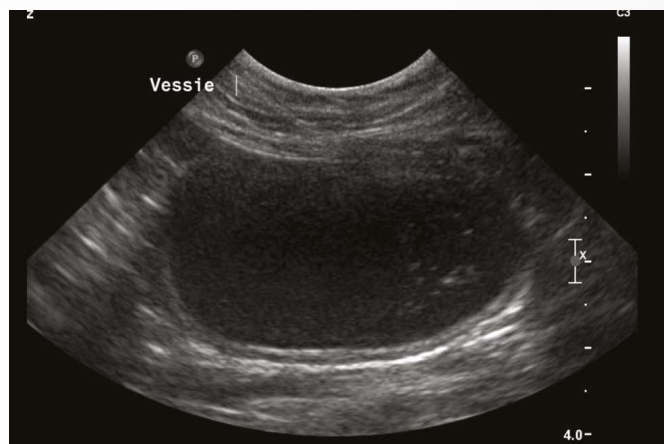


Figure 6: Ultrasound image of Horus at T+2 months

## Discussion and conclusion

The pathogenesis of idiopathic cystitis (IC) is complex. Recent studies have highlighted significant neuroendocrine abnormalities in cats affected by IC, including abnormally increased stimulation of the sympathetic nervous system and dysregulation of the hypothalamic-pituitary-adrenal axis, which explains the inappropriate reactions to stress. Finally, local changes in the urothelium of the bladder have been reported. An excessive increase in bladder permeability, vasodilation, hypercontractility of the bladder muscle and thinning of the glycosaminoglycan layer are the main changes reported. The bladder wall thus becomes sensitised and more sensitive to the composition of the urine. This results in marked inflammation of the bladder wall. In the long term, diet has been shown to have a positive influence: giving wet instead of dry food significantly reduces the frequency of recurrences. 11% of cats on wet food experienced a recurrence compared with 39% of cats on dry food. In cases where it is difficult to get cats to eat wet food, preference should be given to foods that encourage water consumption. Finally, water fountains may also be a way to encourage water consumption.

Nestlé PURINA would like to thank Dr Christelle Maurey for this case study.